ANATOMY & PHYSIOLOGY 12

Kidney Dissection

Name: _____

Partners: _____

_____

_____

This must be submitted along with your written responses at the beginning of next class. Each lab participant must submit their OWN paper.

PURPOSE:

- **To demonstrate safe and correct dissection technique.**
- **To understand the structure of the kidney including the cortex, medulla, renal pyramids, renal columns, major and minor calyxes, ureter and renal vessels and relate it to their functions.**

Introduction:

The human urinary system consists of two kidneys, two ureters, one urinary bladder, and one urethra. This system has many basic functions, all of which occur in the kidneys. One function is to remove nitrogenous wastes (such as creatinine, urea, and uric acid) from the body. Another is to maintain the ion, pH, and water levels in the blood. One product of these processes is urine, a pale yellow fluid containing water and particles such as urea, sodium, potassium, creatinine, and uric acid. Urine moves from the kidneys to the urinary bladder via the ureters, which are essentially tube shaped extensions of the renal pelvis. Urine is stored in the urinary bladder until it leaves the body via the urethra.

Materials (per group):

- Dissection tray, scissors, probes, scalpel
- Dissecting Microscope
- Plastic Gloves and apron
- Pig Kidney
- Coloured pins

Basic Kidney Anatomy

There are four primary components to a kidney:

Renal Capsule: A smooth semitransparent membrane that adheres tightly to the outer surface of the kidney.

Renal Cortex: The region of the kidney just below the capsule. In a fresh kidney the colour of the cortex will be reddish brown.

Renal Medulla: The region deeper into the kidney, beneath the cortex layer. In a fresh kidney it is redder in colour than the cortex. It is segregated into triangular and columnar regions. The triangular regions are the renal pyramids, which should be striated (or striped) in appearance due to the collecting ducts running through them. The columnar regions between the pyramids are the renal columns. These renal columns are where the interlobar arteries are located.

Renal Pelvis: A cavity within the kidney that is continuous with the ureter, which exits from the hilum. The pelvis has portions that extend towards the apexes of the renal pyramids. The primary (large) extensions are the major calyces and the smaller extensions are the minor calyces.

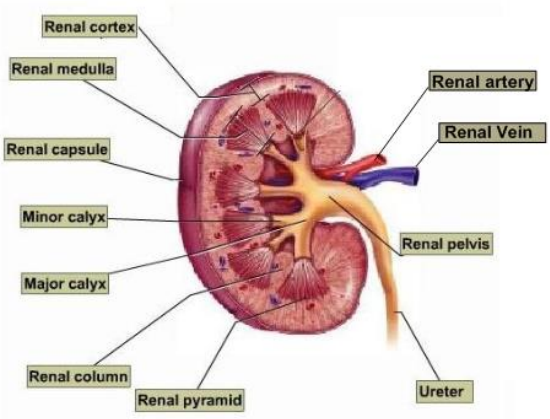

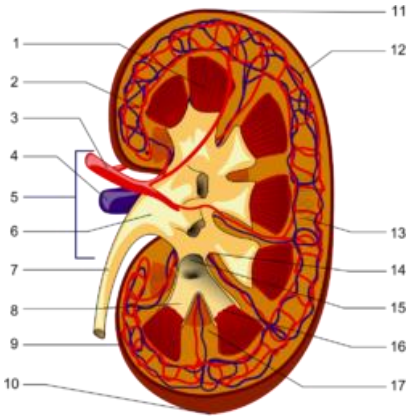

1. Renal triangle
2. Efferent artery
3. Renal artery
4. Renal vein
5. Renal hilum
6. Renal pelvis
7. Ureter
8. Minor calyx
9. Renal capsule
10. Inferior renal capsule
11. Superior renal capsule
12. Afferent vein
13. Nephron
14. Minor calyx
15. Major calyx
16. Renal papilla
17. Renal column

Observation: External Anatomy

1. You'll need a fresh pig kidney for the dissection. Set the kidney down so the flatter side rests on the dissection pan. Observe the whitish adipose (fat) tissue clinging to the renal capsule. These are remnants of the adipose capsule. Use your scissors to remove excess adipose tissue around the hilus region, and the probe to help you identify the ureter and any blood vessels located in the hilus region. Complete two biological drawings of two views of the exterior of the kidney.

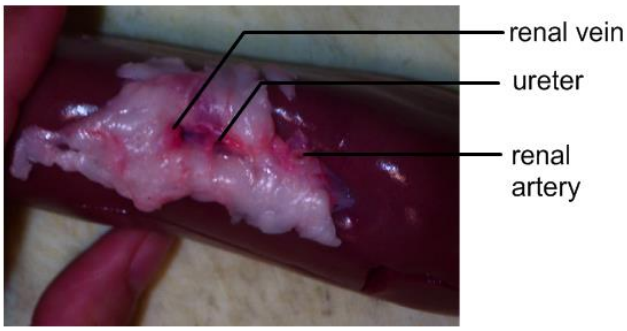



Drawing of first view of the kidney	Drawing of second view of the kidney

Observation: Internal Anatomy

2. Cut the kidney in half longitudinally using the knife or with short repeated strokes of the scalpel.

3. Examine the interior structure of the kidney. Identify & label the following structures with the coloured pins. It may be useful to trace the vessels from the hilus region with a blunt probe to help with identification. Call your teacher over when complete.

Structure	**Colour**	**Correctly labelled?**
Cortex	*blue*	
Medulla	*black*	
Renal Pyramids	*yellow*	
Renal Columns	*white*	
Major Calyx	*red*	
Minor Calyxes	*green*	
Ureter	*clear*	
Renal Vessels	*#1*	

4. Complete a biological drawing of the interior of one half of the kidney. Include labels where appropriate.

Drawing of internal cross-section of kidney

5. Dispose of the kidney in the waste bag provided. Wash all dissecting equipment and return. Wash your hands thoroughly with warm soap and water.

Summary Questions

There is no right or wrong answer for these question – it is more about your thought process and description found in your answer. You will likely need more space to fully express your answer so please attach your answers to this document.

1. Which part(s) of the kidney looked exactly as you expected? And why?

2. Which part(s) of the kidney looked different than you expected? And why?

3. Which part of the kidney did you find most interesting to see up close - so that you could both see and touch it? And why?

4. What was most beneficial about seeing the kidney in this way? In other words, how does it enhance your understanding of the urinary system? Be specific!

5. What will you do either the same or different next time so that you get the most out of the dissection experience?

Performance Based Assessment **NAME:** _____

	Beginning	Developing	Accomplished	Exemplary
Labeling	Many structures are incorrectly labelled or not labelled at all	The majority (more than 1/2) of structures accurately labelled	Almost all structures accurately labelled	All structures accurately labelled
Cortex, medulla, renal pyramids, renal clumns, major calyz, minor calyxes, ureter, renal vessels				
Diagrams	Kidney structures are not labeled in most drawings Diagram is not neat nor realistic and is not drawn in pencil.	Kidney structures are incorrectly labeled in most drawings Diagram is may not be neat or realistic and is not drawn in pencil.	Kidney structures are correctly labeled in at most drawings Diagram is neat and somewhat realistic, but may not be not drawn in pencil	Kidney structures correctly labeled in all drawings Diagram is neat and realistic and drawn in pencil
Summary Questions	Does not demonstrate a basic response to the questions. Some questions may be incomplete or unanswered.	Basic responses to the questions. Minimal detail or thought included.	A solid development of the responses to the questions. Some detail or thought shown.	Complete and in depth, detailed development of the responses to the questions.